

**RESOURCE PAPER FOR DANCERS AND TEACHERS**

# **Turnout for Dancers: Hip Anatomy and Factors Affecting Turnout**

VIRGINIA WILMERDING, PH.D., AND DONNA KRASNOW, M.S. WITH THE IADMS DANCE  
EDUCATORS' COMMITTEE, 2011.

**CONTENTS:**

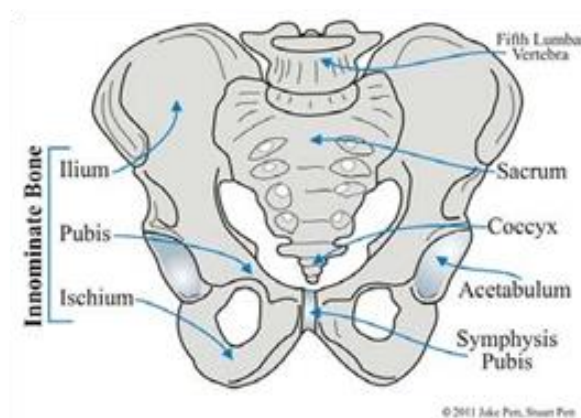
1.	INTRODUCTION	2
2.	BONES OF THE HIP JOINT	2
3.	STRUCTURE OF THE HIP JOINT	4
4.	CAPSULE AND LIGAMENTS OF THE HIP JOINT	5
5.	MUSCLES OF THE HIP THAT CREATE TURNOUT	6
6.	FACTORS AFFECTING TURNOUT	7
7.	INDIVIDUAL ANATOMICAL VARIATIONS	10
8.	CONCLUSION	11
9.	APPENDIX OF TERMINOLOGY	11
10.	CREDITS	13
11.	RECOMMENDED READING	14
12.	THE AUTHORS	14

# 1. INTRODUCTION

Turnout describes the position of the legs, used in many forms of dancing, in which each leg is rotated in the opposite direction from the other and facing away from the midline of the body as observed from the front. “Ideal” turnout traditionally has been identified as 180 degrees of outward rotation (also called external rotation and lateral rotation) of both legs combined. An awareness of basic anatomy will help in the understanding of the limitations of this expectation. The paper is divided into several sections: (1) Bones of the hip joint, (2) Structure of the hip joint: the ball and socket, (3) Capsule and ligaments of the hip joint, (4) Muscles of the hip that create turnout, (5) Factors affecting turnout, and (6) Individual anatomical variations. It is important to begin with an understanding of the bones, so that the perception of turnout is structurally clear. Dancers can safely execute the skills requiring external rotation only if they have a sound knowledge of optimal individual skeletal and soft tissue range of motion capabilities. It is from ideas or images of movement tasks that the dancer can achieve the most efficient dynamic movement, and not by trying to coordinate and control individual muscle activation, or to achieve some ideal of perfection that is anatomically unrealistic. For those readers unfamiliar with the movement terminology used in this paper, there is an appendix of terms at the end.

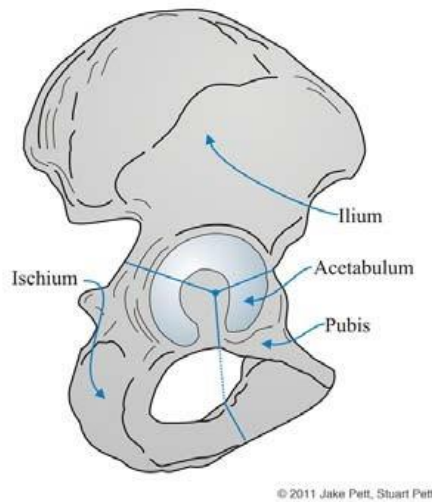
# 2. BONES OF THE HIP JOINT

The **pelvis** is made up of two halves, the **innominate bones**, or **hip bones**. Each innominate bone is formed from the fusion of three bones: **ilium**, **pubis**, and **ischium**. Each of the three bones contributes to the hip socket or **acetabulum**, like a pie with three slices. Fusion of these three bones, forming one solid bone, does not occur until about the 16th year of life. The pubic bones connect in front by way of the **symphysis pubis**, a joint that connects these bones with a small disc made of cartilage. See Figures 1 and 2.



*Figure 1: Pelvis, front view*

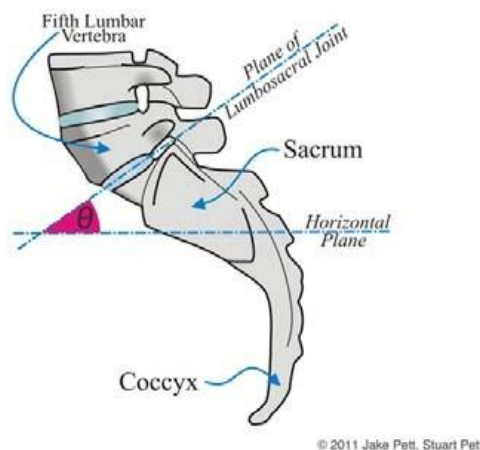
Jake Pett, B.F.A., and Stuart Pett, M.D.



*Figure 2: Pelvis, side view*

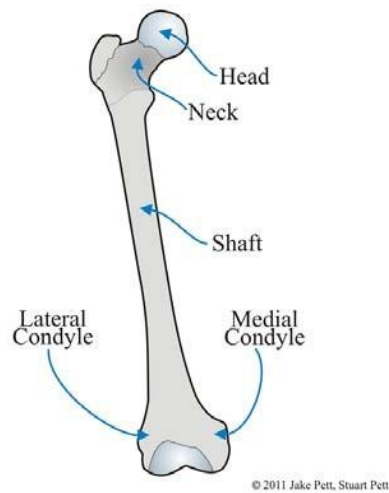
Jake Pett, B.F.A., and Stuart Pett, M.D.

Between the two innominate bones is the foundation for the pelvis, the **sacrum**. See Figure 3. The sacrum is a triangular-shaped bone that comprises five fused bones at the lower end of the spinal column. Lower still is the coccyx, four fused bones, often referred to as the tailbone. Dense ligaments hold the pelvis to the sacrum at junctions known as the sacroiliac joints, which are slightly moveable. Note in Figure 3 how the sacrum has a deep forward angulation relative to the final or 5th lumbar vertebra. This angle is almost 30 degrees on average.



*Figure 3: Lumbosacral joint*

The **femur** is more commonly known as the thigh bone. See Figure 4. Although all femurs share certain structural characteristics and landmarks, each person's anatomy is unique. The femur consists of the round head, the neck, the shaft and two condyles (lateral and medial) at the base of the femur. The femur is the longest bone in the body, and though it has movement in all three planes like the shoulder joint, it has much more limited range of motion.

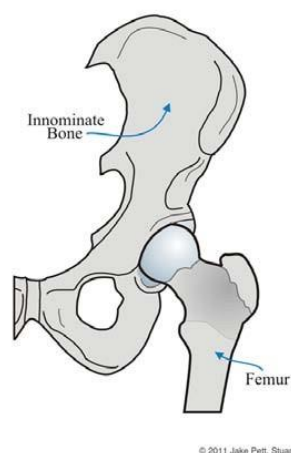


*Figure 4: Femur (thigh bone)*

Jake Pett, B.F.A., and Stuart Pett, M.D.

### 3. STRUCTURE OF THE HIP JOINT

The **hip joint** itself includes two main parts, the **ball and socket**. The ball of the hip joint consists of the round head of the **femur** or thigh bone. See Figure 5. The hip socket (described previously and shown in Figure 2), or **acetabulum**, forms approximately half of a sphere. It is deepened by a horseshoe-shaped piece of cartilage called the labrum. The cartilage is thicker around the socket rim, tapering to a thin layer toward the joint center.



*Figure 5: Hip joint*

Jake Pett, B.F.A., and Stuart Pett, M.D.

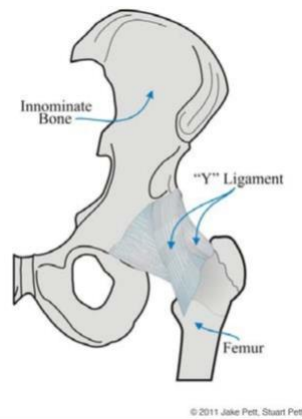
## 4. CAPSULE AND LIGAMENTS OF THE HIP JOINT

Enclosing the bones of the hip joint is the **hip joint capsule**, a sleeve of fibrous connective tissue. The pelvic end of this sleeve is attached around the perimeter of the bony acetabular socket. The thigh end of the capsule attaches at the far end of the neck of the femur. The capsule holds the femoral head in the hip joint and stabilizes it and does provide some restriction of motion. It is lined by a synovial membrane, which secretes lubricating synovial fluid.

The capsule is reinforced by three major ligaments, which are denser bands of connective tissue. Each of the three ligaments is attached to one of the three bones of the hip socket. The attachments of each of these can be identified by its name: the **iliofemoral ligament** extends from the ilium on the pelvis to the femur, the **pubofemoral ligament** connects the pubic bone to the femur, and the **ischiofemoral ligament** extends from the ischium to the femur. All three of these ligaments become taut in hip extension (as the leg moves backwards in grand battement derrière for example), and therefore contribute to stability while standing. All three of these ligaments become lax as the hip moves into flexion (as the leg moves forwards or in grand battement devant for example).

The iliofemoral ligament (also called the Y ligament) extends diagonally across the front of the hip joint and it is the strongest ligament in the body. See Figure 6. It primarily strengthens the front of the hip capsule, resisting hip extension (raising the leg behind the body to arabesque) and it also inhibits external rotation. This is why it is so difficult to turn out the leg in full arabesque. The pubofemoral ligament strengthens the back portion of the hip capsule, primarily resisting hip abduction (raising the leg sideways to à la seconde). The ischiofemoral ligament resists adduction (moving the leg across the midline) and medial rotation.

The hip is designed more for stability than mobility, the opposite of the situation in the shoulder joint. Consequently, the hip socket is deeper, and the capsule and ligaments are stronger than at the shoulder.



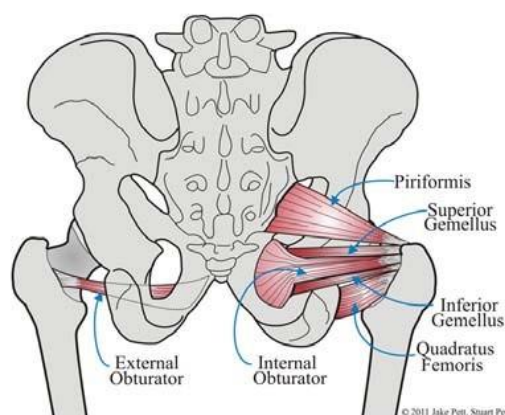
*Figure 6: Y ligament*

Jake Pett, B.F.A., and Stuart Pett, M.D.

## 5. MUSCLES OF THE HIP THAT CREATE TURNOUT

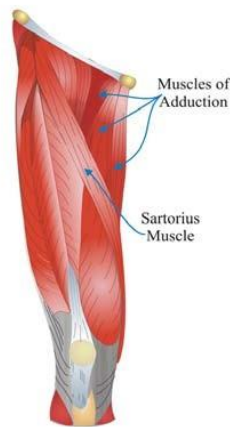
The most obvious muscles of the hip are located in the buttocks. The large gluteal muscles act as hip extensors (taking the leg to the back such as in arabesque) and external rotators.

In contrast, the muscles that are more important for turnout, the deep lateral rotators, are small and are buried under the gluteus maximus. See Figure 7. These six lateral rotator muscles are attached to different parts of the pelvis. They all then run laterally, spanning the back of the hip joint capsule and the ischiofemoral ligament. Finally, they all attach on or adjacent to the greater trochanter of the femur. In addition to the six lateral rotators and the gluteus maximus, there are additional muscles around the hip that contribute to external rotation. The sartorius is an external rotator that is thought to be particularly active when the hip is flexed or abducted such as in a passé or front attitude. See Figure 8. The adductor muscles on the inner thigh may contribute to external rotation when the femur is in extension and is already turned out by the primary external rotators. Straightening the legs from the bottom of plié is a good example of using adductors in outward rotation.



*Figure 7: Hip outward rotators*

Jake Pett, B.F.A., and Stuart Pett, M.D.



*Figure 8: Thigh muscles*

Jake Pett, B.F.A., and Stuart Pett, M.D.

The function of all six deep rotator muscles is to laterally rotate or turn out the leg, relative to the pelvis. They achieve this goal by pulling the femur's greater trochanter backwards, that is, toward the back of the pelvis. It is often difficult for dancers to isolate the contraction of this muscle group. It is not necessary to tighten or "clench" the gluteals to activate the deep lateral rotators.

## **6. FACTORS AFFECTING TURNOUT**

Teachers encourage their students to turnout only from the hips, and as a working cue, this is sound advice. However, anatomically, there are contributions to a fully turned out leg that come from the structure of the knee and lower limb joints. Research suggests that on average, 60% of turnout is created by outward rotation of the hip. Twenty to thirty percent of turnout may then emanate from the ankle, with the remaining percentage

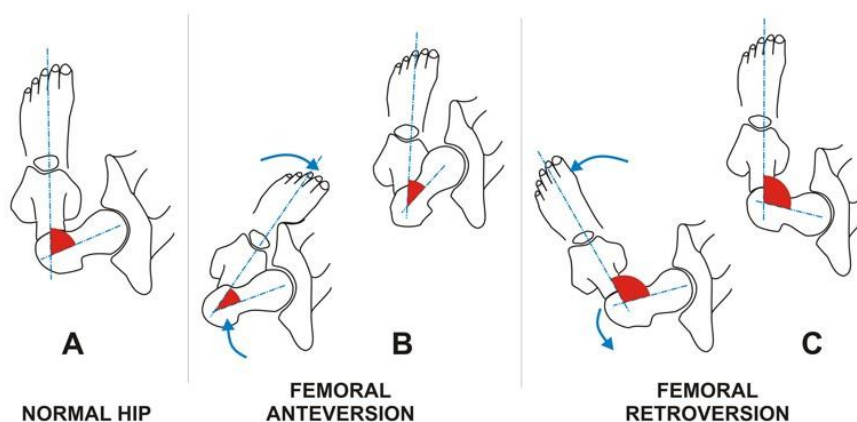
created by the tibia and knee joint. For an understanding of how the lower leg contributes to turnout in the extended (standing) position, please read about the “screw home” mechanism in the section called Individual anatomical variations below. The limiting anatomical structures include bones, ligaments, the joint itself, and muscles surrounding the hip joint.

There are five main factors that affect turnout:

## 1. ANGLE OF FEMORAL ANTEVERSION

On average, the neck of the femur is angled 15 degrees forward relative to the shaft of the femur. See Figure 9A. An increase in this anterior angulation, called anteversion, often will cause someone to toe in when they walk. See Figure 9B. This is often referred to as being pigeon toed. In children who are born with more anteversion, the orientation of the femoral shaft in the hip socket makes the knees face towards each other when standing or walking. In ballet class, when they turn out their legs from the hip, the knees face the front, leaving little additional hip rotation to create the expected angle of outward rotation visible at the feet.

However, a decrease in this angulation, called retroversion, will allow one to have greater turnout. See Figure 9C. Children born with retroversion have a much easier time with turnout. Just standing in parallel, the knees and feet tend to face outward. By adding external rotation at the hip, they can achieve a larger angle of outward rotation visible at the feet than the average person. Currently, most researchers agree that these are not conditions that can be altered with training.





### *Figure 9: Femoral anteversion and retroversion*

from Dance Anatomy and Kinesiology, by Karen Clippinger, with permission from Human Kinetics Publishers

## **2. ORIENTATION OF THE ACETABULUM**

The socket of the hip faces out to the side and somewhat forward, but there are individual variances. The socket that tends to face more directly to the side with a less forward facing will allow a greater amount of turnout to come from the hip.

## **3. SHAPE OF THE FEMORAL NECK**

The neck of the femur is subject to some variability. A longer and more concave neck allows a greater range of motion at the hip; it is less likely to contact the outer edge of the acetabulum in turnout and is therefore considered to be advantageous. A shorter and less concave neck will have the opposite effect and limit turnout potential.

## **4. ELASTICITY OF ILIOFEMORAL OR Y LIGAMENT**

As previously mentioned, the three ligaments surrounding the hip restrict extension. The iliofemoral ligament, strong and with minimal elastic properties, opposes extension of the hip. This ligament also resists lateral rotation or turnout of the hip. Thus, the more the hip is extended to the back, the greater the resistance to turnout. It is controversial whether attempts should be made to alter the flexibility of this ligament, as it may alter its capacity to stabilize the hip. In order to gain greater turnout when standing, dancers sometimes flex the hips by tilting the pelvis forward. This flexed position creates some laxity in the ligaments, providing slack that can be used to increase hip rotation. However, this attempted compensation creates a position of lumbar lordosis (low back sway), thrusts the buttocks backward, and is aesthetically undesirable and potentially damaging. Additionally, with a pelvis in this tilted position, the angle for using the deep external rotator is less effective.

## **5. FLEXIBILITY AND STRENGTH OF THE MUSCLE-TENDON UNIT**

The muscles surrounding the hip, if unnaturally tight, may restrict a dancer's ability to achieve an acceptable degree of turnout. Proper stretching techniques will enable dancers to achieve their maximal turnout potential. Similarly, adequate strength and optimal activation of the hip external rotators may help dancers to achieve their potential turnout. Part Two of this resource paper, [Turnout for Dancers: Supplemental Training](#), provides an array of exercises and images to enhance the flexibility, strength and motor control of the musculature that supports turnout.

## 7. INDIVIDUAL ANATOMICAL VARIATIONS

Summative contributions of the **hip**, **knee**, **tibia**, and **foot** create the dancer's turnout. In most cases, dancers do not possess perfect turnout, or complete external rotation from the hip, without associated adjustments to support the rotation through the rest of the lower leg.

In weightbearing positions (standing), when the knee is straightening from a flexed position to full extension, the medial condyle stops moving before the lateral condyle. The result is that the femur inwardly rotates on the tibia in those last few degrees of extension. The knee joint is then in a locked position, known as the "screw home" mechanism. In essence, the lower leg and foot will now appear further externally rotated than the knee and thigh. When the knee initiates flexion, a small muscle at the back of the knee called the popliteus externally rotates the femur so that it can once again line up with the lower leg. Note that in the flexed knee, the lower leg can externally rotate because the primary ligaments are lax. It is unwise to rotate the lower leg in this manner, and then straighten the knee into standing. Examples of this action include the dancer closing a tendu into 5th position plié or shifting the heels forward at the base of a grand plié. This action of straightening the knee from the flexed, rotated position puts undue pressure on these protective ligaments.

At the **tibia**, torsion is defined as an axial twist of the tibia or shinbone. The twist can occur internally or externally. Internal tibial torsion occurs when the tibia medially rotates; this condition will adversely affect the ability of a dancer to achieve turnout. It is presumed that young dancers who have internal tibial torsion will self-select away from dance forms that require turnout due to frustration or pain in trying to achieve this goal. External tibial torsion has been measured as widely varied as 16 to 60 degrees. Further, dancers tend to have differing amounts of tibial torsion in each leg. This will mean that turnout on each

leg will be varied. Most health care practitioners advise that one assumes the rotation of the less turned out leg for symmetry and injury prevention.

The small bones in the **foot** allow a gliding action to occur at the arch. It is not uncommon to see dancers force the lower limbs beyond the normal limits of the hip's range of motion, creating a compensating action called pronation or "rolling in" of the feet to achieve the perception of greater or perfect turnout. This is also referred to as "forcing the feet". Dancers are more prone to force the feet in 5th position than other leg positions. Naturally, abnormal alignment ensues, causing medial stress along the leg and knee, and is quite possibly linked to increased injury potential. The injury rate for the foot and ankle complex is the highest of all joint systems. Thus, this strategy of allowing the foot to pronate as a compensatory mechanism for turnout is discouraged by teachers and health care practitioners alike.

## **8. CONCLUSION**

It is important to remember that external hip rotation and turnout are not the same thing. Turnout is understood to be a necessary component of many dance idioms. It is presumed to be "perfect" when each leg is rotated 90 degrees laterally. However, researchers agree that available external hip rotation coupled with the various contributions of the tibia and foot rarely add up to this magic number. As there is a vast array of individual differences in human bodies, there are many considerations in determining how to safely optimize turnout. As dance teachers and dancers learn the anatomical and biomechanical mechanisms underlying turnout, both general and individual, they will be more able to understand, evaluate and apply sound methods to improve turnout and optimize dynamic function.

In the resource paper, [Turnout for Dancers: Supplemental Training](#), specific exercises for conditioning and recruitment of primary and supporting muscles involved in turnout are described. The paper also considers issues of core support and alignment as related to turnout.

## **9. APPENDIX OF TERMINOLOGY**

## PLANES OF MOVEMENT

**Sagittal:** The vertical plane that divides the body into right and left sides, sometimes called the Wheel Plane.

**Frontal or coronal:** The vertical plane that divides the body into front and back portions, sometimes called the Door Plane.

**Transverse or horizontal:** The horizontal plane that divides the body into upper and lower portions, sometimes called the Table Plane.

## MOVEMENT TERMS:

**Flexion:** The decrease in the angle of two articulating bones, in the sagittal plane. Example: From standing position, lifting one leg to a parallel passé; this involves flexion of both the hip and the knee joints. Curving forward is flexion of the spine.

**Extension:** The increase in the angle of two articulating bones, in the sagittal plane; the return to neutral from the flexed position. Example: Bringing the leg from parallel passé back to standing position.

**Hyperextension:** Continuing of extension beyond anatomical neutral. Example: Arabesque involves hyperextension of the hip and the low back, which arches to achieve the full range of motion.

**Abduction:** The movement of a bone in the frontal plane away from the midline of the body. Example: Lifting the arms out to second position, or moving the leg directly side away from the body.

**Adduction:** The movement of a bone in the frontal plane towards from the midline of the body. Example: Lowering the arms from second position to straight down or moving the leg from side back to neutral standing position.

**Outward rotation:** Also called lateral or external rotation, the movement of a bone around its own axis, away from the midline of the body. Example: Both the hip joint and the shoulder outward rotate: standing in classical first is a position of outward

## MOVEMENT TERMS CONTINUED:

**Inward rotation:** Also called medial or internal rotation, the movement of a bone around its own axis, towards the midline of the body. Example: Both the hip joint and the shoulder inward rotate.

**Supination:** This movement term is used for both the forearm (radioulnar joint) and for the foot. Movement of the forearm in which the palm is turned anteriorly, or away from the midline of the body. When standing, supination occurs as the foot rolls outwards, placing most of the weight onto the outside of the foot and raising the arch. Supination combines inversion (moving the soles of the feet medially) and adduction of the foot. Example: When the foot is “sickled” it is supinated.

**Pronation:** This movement term is used for both the forearm (radioulnar joint) and for the foot. Movement of the forearm in which the palm is turned posteriorly, or towards from the midline of the body. When standing, pronation occurs as the foot rolls inward, placing most of the weight onto the inside of the foot and lowering the arch. Pronation combines eversion (moving the soles of the feet laterally) and abduction of the foot. Example: When the foot is “winged” it is pronated.

**Plantar flexion:** Bending at the ankle joint in the sagittal plane, so that the toes move away from the front of the shinbone. Example: Dancers call this “pointing the foot”. Relevé is also an example of plantar flexion.

**Dorsiflexion:** Bending at the ankle joint in the sagittal plane, so that the toes move

## 10. CREDITS

All drawings by Jake Pett, B.F.A., and Stuart Pett, M.D.

Figure 9 has been derived from *Dance Anatomy and Kinesiology*, by Karen Clippinger, with permission from Human Kinetics Publishers.

Appendix of terminology taken from *Conditioning with Imagery for Dancers*, by Donna Krasnow and Jordana Deveau, used courtesy of Thompson Educational Publishing, Inc.

## 11. RECOMMENDED READING

Calais-Germain B. *Anatomy of Movement*. Seattle, WA: Eastland Press, Inc., 1993.

Clarkson PM, Skrinar M. *Science of Dance Training*. Champaign, IL: Human Kinetics Publishers, Inc., 1988.

Clippinger K. *Dance Anatomy and Kinesiology*. Champaign, IL: Human Kinetics Publishers, Inc., 2007. Fitt SS. *Dance Kinesiology* (2nd ed). NY: Schirmer Books, 1996.

Grossman G, Krasnow D, Welsh TM. Effective use of turnout: Biomechanical, neuromuscular, and behavioral considerations. *J Dance Educ.* 2005;5(1):15-27.

Hoppenfeld S. *Physical Examination of the Spine and Extremities*. East Norwalk, CT: Appleton-Century- Crofts, 1976.

Krasnow D, Deveau J. *Conditioning with Imagery for Dancers*. Toronto, ON: Thompson Educational Publishers, 2010.

Moore KL. *Clinically Oriented Anatomy*. Baltimore, MD: Williams and Wilkins, 1984.

Ryan AJ, Stephens RE. *Dance Medicine: A Comprehensive Guide*. Chicago, IL: Pluribus

Press, 1987. Shell CG (ed). *The Dancer as Athlete: the 1984 Olympic Scientific Congress Proceedings Volume 8*.

Champaign, IL: Human Kinetics Publishers, 1984.

Wadler G (ed). *The Healthy Dancer: ABT Guidelines for Dancer Health*. New York, NY: ABT Foundation, 2008.

## 12. THE AUTHORS

Virginia Wilmerding is at the University of New Mexico, Albuquerque, New Mexico, USA.

Donna Krasnow is at York University, Toronto, Ontario, Canada and California State University, Northridge, California, USA

This paper is dedicated to the memory of Marjorie Moore, Ph.D.

This paper may be reproduced in its entirety for educational purposes, provided acknowledgement is given to the "International Association for Dance Medicine and Science."

©2011 IADMS, Donna Krasnow, M.S., and Virginia Wilmerding, Ph.D.